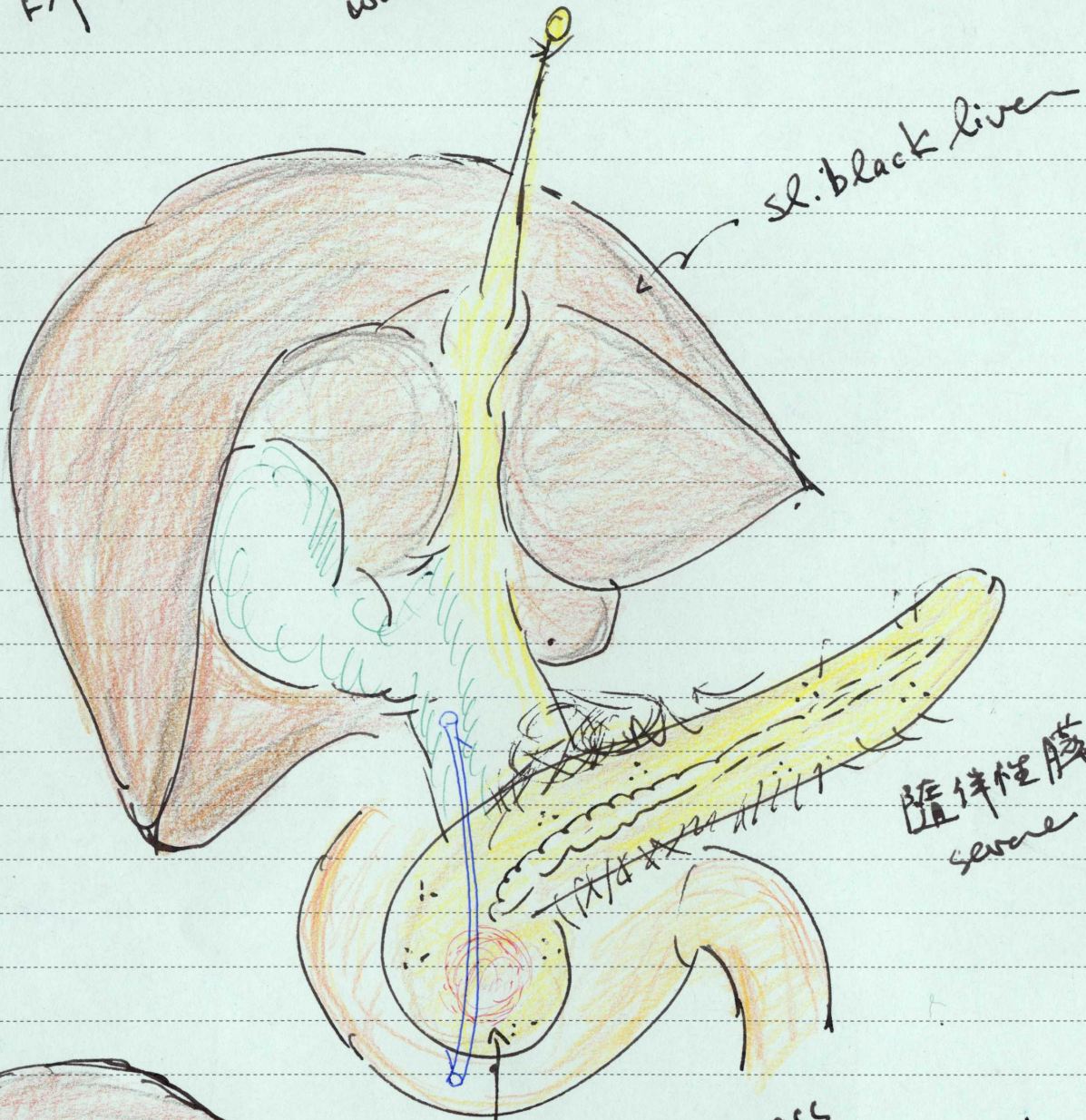


Exploration: Ho. Po

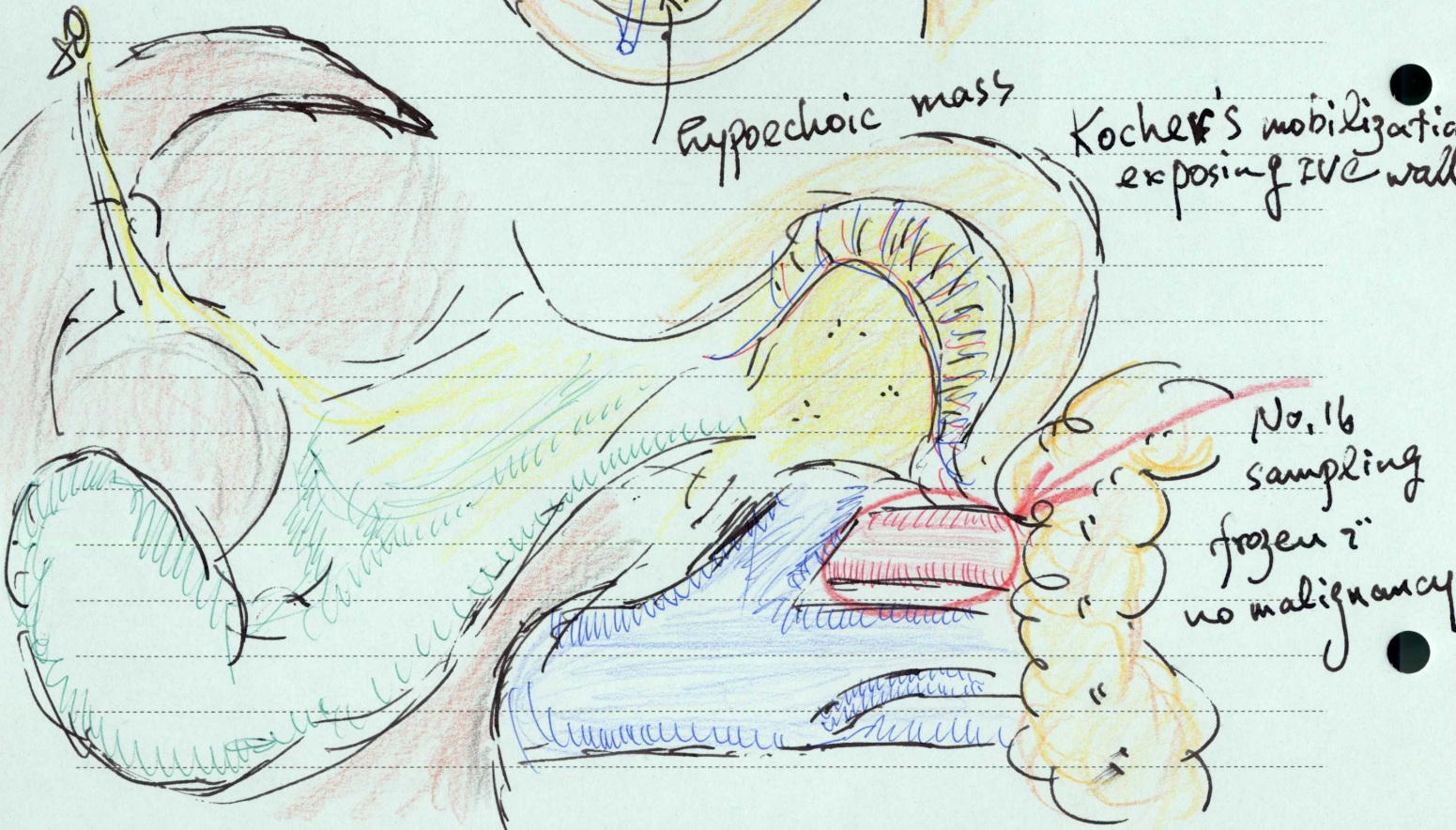
washing cytology: negative

①



hypoechoic mass

Kocher's mobilization
exposing IVC wall



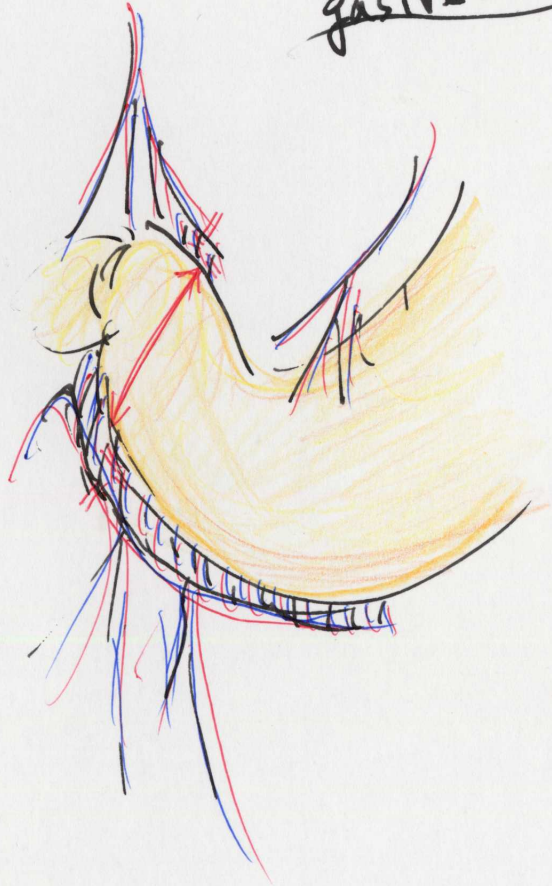
panc p. ja drainage
vein to the
gastrocolic trunk
膵臓静脈

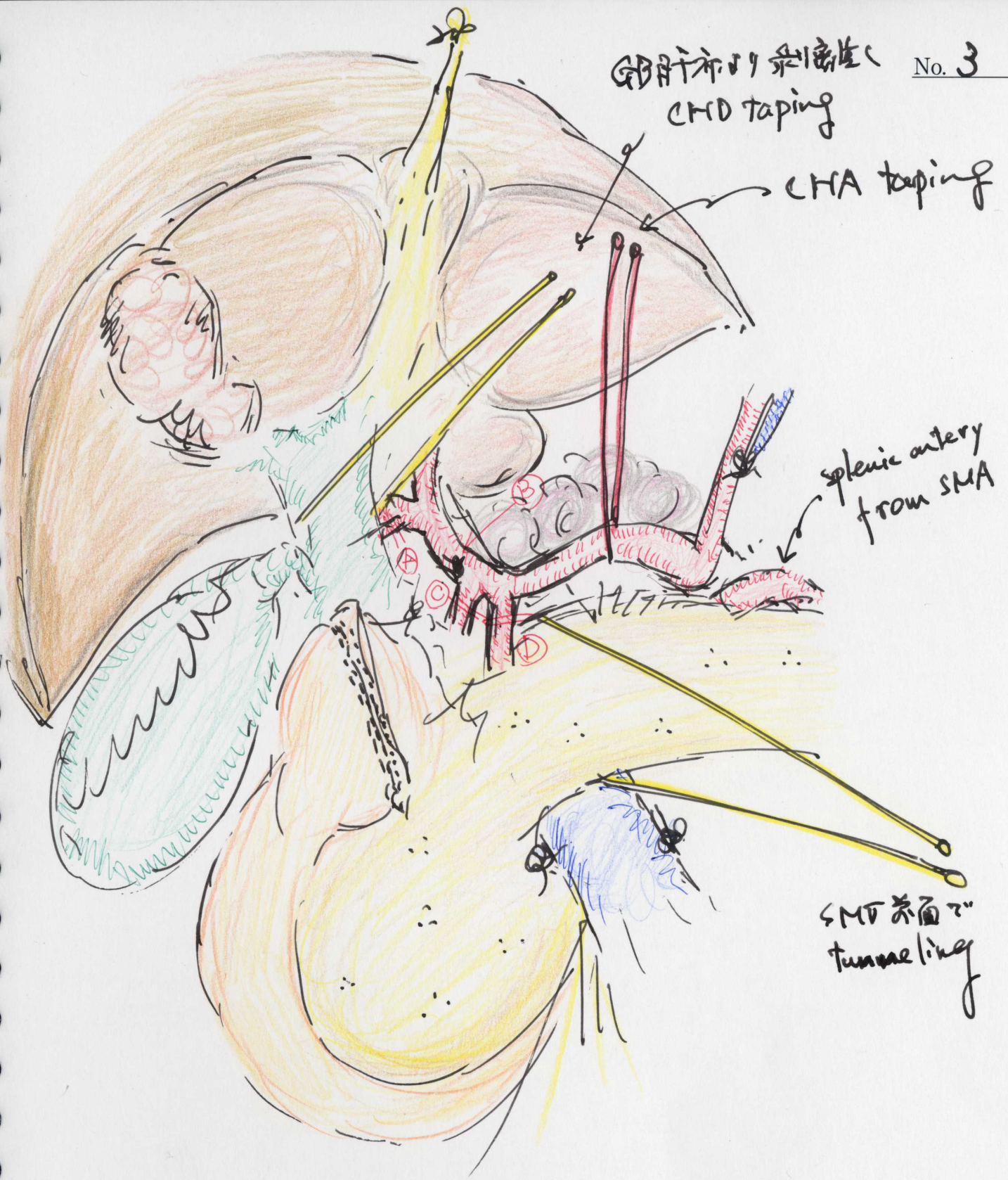
ovary vein
卵巣静脈

middle colic vein
中腸静脈

accessory right colic vein
副右腸静脈

gastrectomy






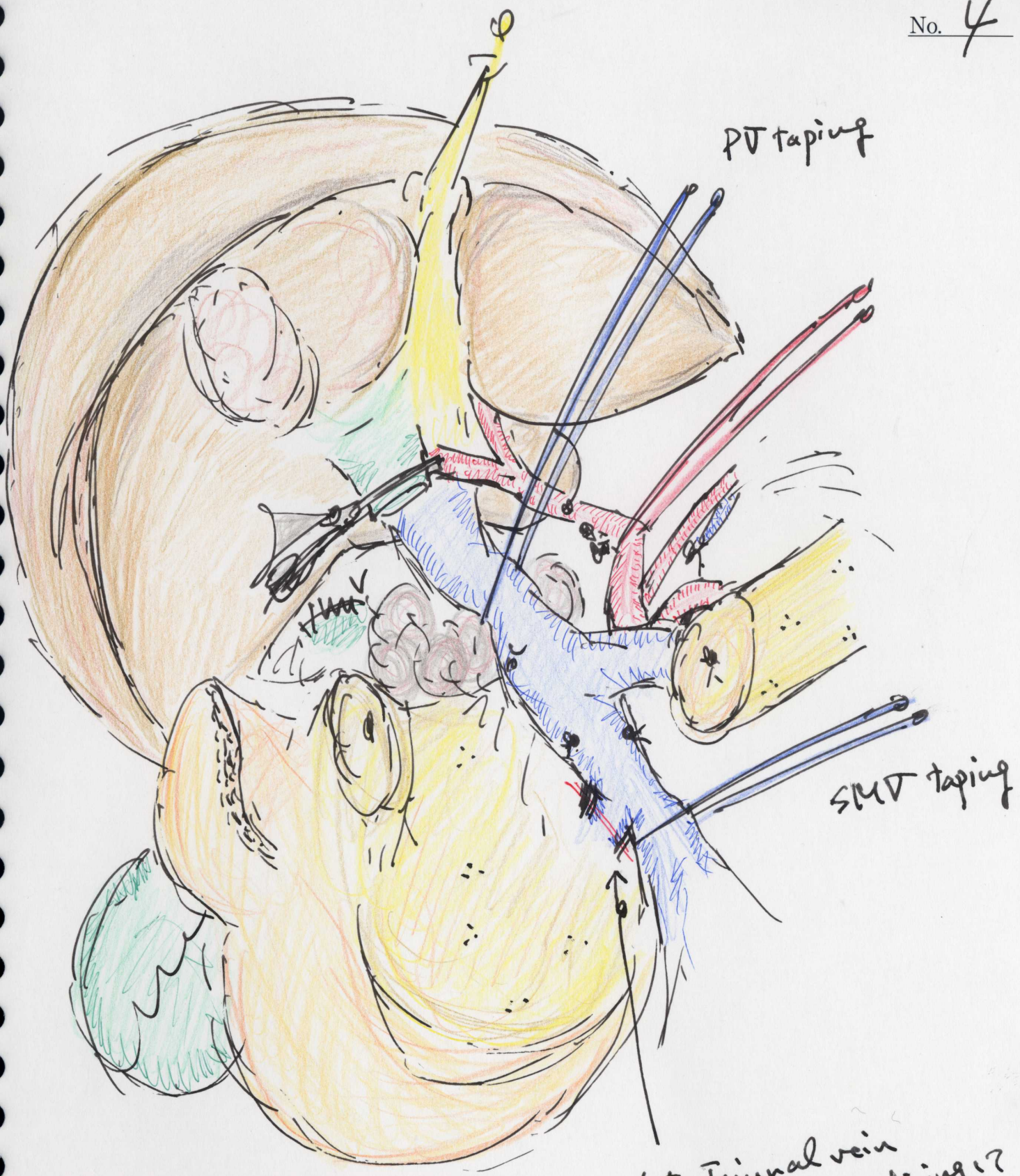
splenic artery from SMA

SMT 表面の tunneling

- (A) cystic artery 糸密性
- (B) 胃 gastric artery 糸密性
- (C) PSPDA ligation + Transfixing 糸密性
- (D) GDA ligation + Transfixing 糸密性

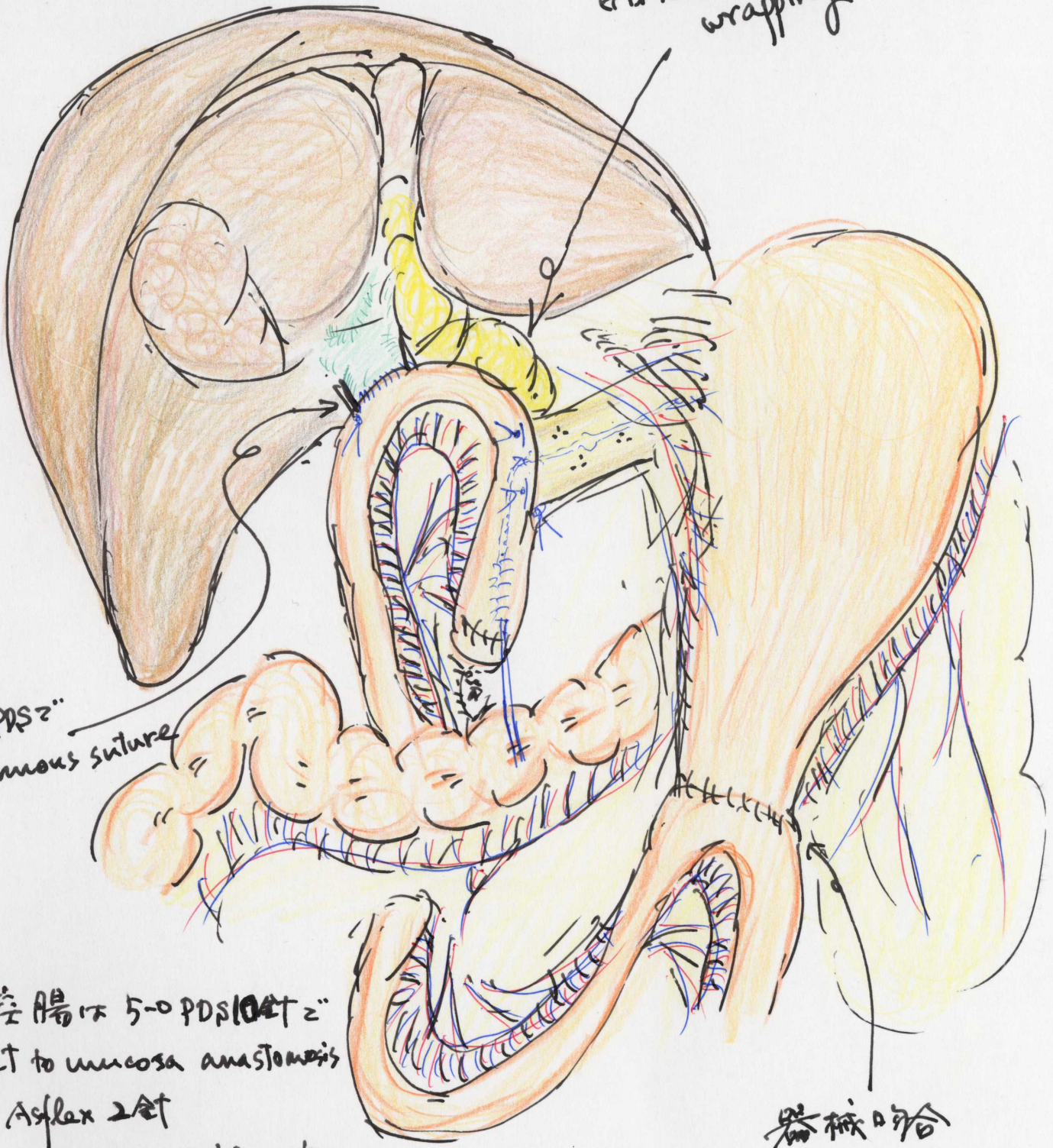


celiaca to 110's
 SMA ni 3/4 ni
 LN, connective tissue
 dissection
 A IPPA + 1st JA
 B 2nd JA
 ligation + transfixing
 ni to ouchi
 ↓
 mesenterium ni
 to ouchi ni jejunum
 ni ouchi ni
 to ouchi ni
 (SMA plexus ni
 ouchi ni)



CHD 離断
 frozen? 止血带
 no malignancy

1st Jejunal vein
 ligation + transfixing?
 to 3rd part

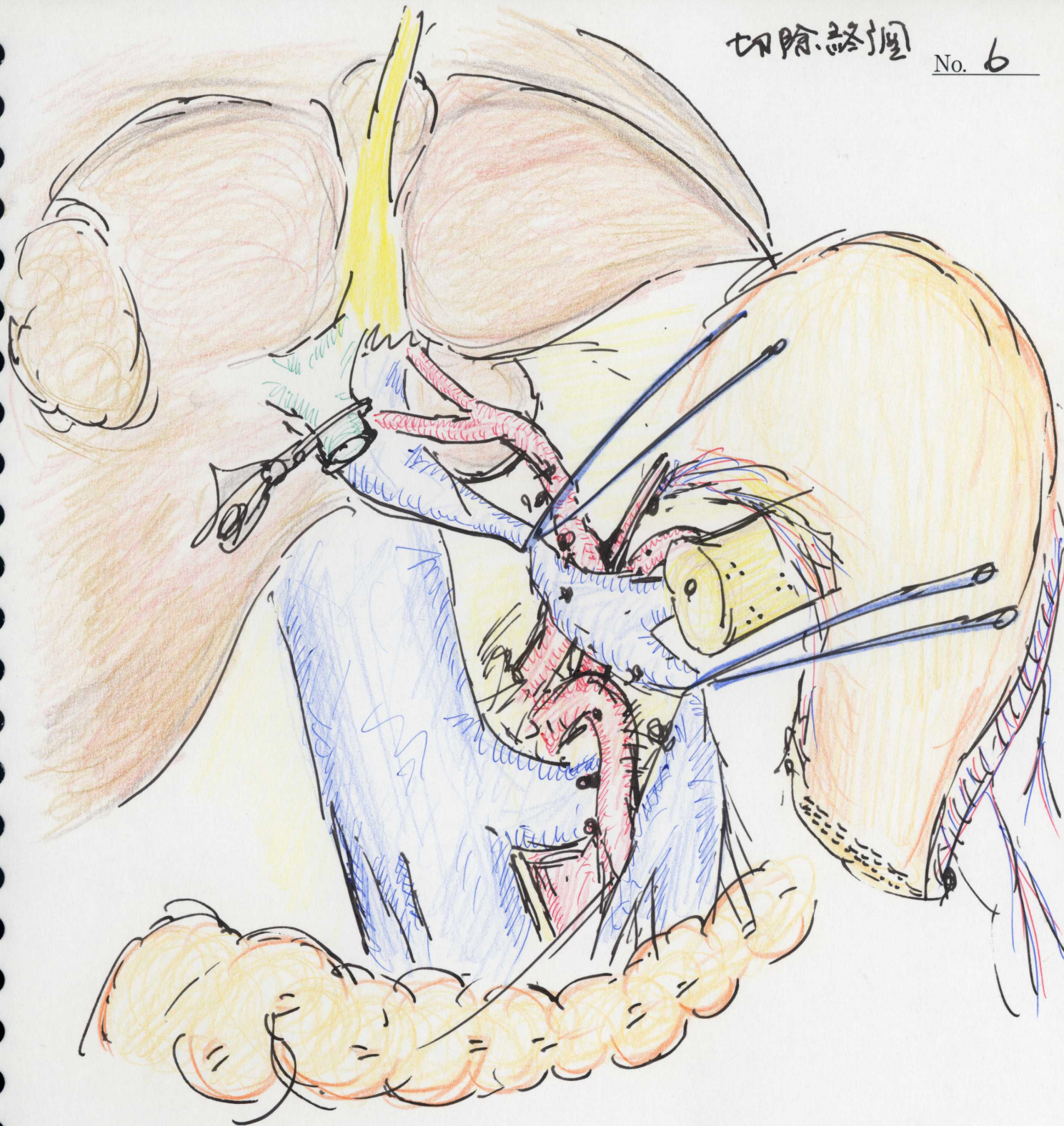


5-0 PDS continuous suture

器械吻合

- 膵空腸に 5-0 PDS 10針を
- duct to mucosa anastomosis
- 3-0 Asflex 2針
- 4-0 prolene を Asflex の直に
- 膵下縁を補強した。
- (Blumgart 変法)
- Hemostasis 不徹底。lavage.
- mesenterium を縫合固定
- drain を留置して閉創。op. 終了

Tsuyoshi
Sano



frozen & panc 断端 no malignancy